ARMD ñ ?

ARMD (Age-Related Macular Degeneration)

ARMD Ľ ñ

ARMD - σ ( ) ( )

- σ ARMD ŭ (90%
- ARMD ŭ (10%

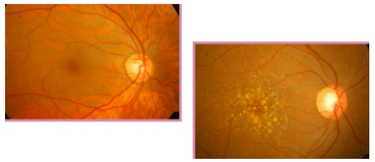

Photograph of a patient with a normal retina and a patient with yellow deposits (drusen) at the macula due to dry ARMD

ARMD ñ ?

σ ARMD (Drusen) (geographic atrophy)

ARMD ï :

ARMD :

ARMD Ī

(Amsler Grid Test)

ARMD

ARMD ñ ?

ARMD

(Choroidal Neovascular Membrane - CNVM)

(scar)

Retina of a patient with wet ARMD showing homorrhage and a choroidal neovascular membrane at the macula

ARMD ï :

ARMD Ī Ī ?

:

- (FFA)
- (OCT)

ARMD :

1. -VEGF ñ :
   - ŭ
   - Pegaptanib (Macugen), Ranibizumab (Lucentis), Bevacizumab (Avastin)
   - –
2. (PDT) - Verteporfin (Visudyne):
   - (verteporéîn) E
   - ŭ
3. Ň Ā (PDT -VEGF ñ):

:

ARMD Ī

E, -3 , Ŭ , , - Q10, σ - σ , (EGCG) ARMD Q

ARMD Ą D â è

- :
- ( ):
- :

ICARE EYE HOSPITAL AND POST GRADUATE INSTITUTE
(A UNIT OF ISHWAR CHARITABLE TRUST)

- ñ (ARMD)